Eur J Nucl Med Mol Imaging (2013) 40:486–495
DOI 10.1007/s00259-012-2298-2

ORIGINAL ARTICLE

PET imaging with a [^{68}Ga]gallium-labelled PSMA ligand for the diagnosis of prostate cancer: biodistribution in humans and first evaluation of tumour lesions

A. Afshar-Oromieh · A. Malcher · M. Eder · M. Eisenhut · H. G. Linhart · B. A. Hadaschik · T. Holland-Letz · F. L. Giesel · C. Kratochwil · S. Haufe · U. Haberkorn · C. M. Zechmann

Received: 21 August 2012 / Accepted: 6 November 2012 / Published online: 24 November 2012
© Springer-Verlag Berlin Heidelberg 2012

Abstract
Purpose Prostate-specific membrane antigen (PSMA) is a cell surface protein with high expression in prostate carcinoma (PC) cells. Recently, procedures have been developed to label PSMA ligands with ^{68}Ga, ^{99m}Tc and $^{123/124/131}$I. Our initial experience with Glu-NH-CO-NH-Lys-(Ahx)-[^{68}Ga(HBED-CC)](^{68}Ga-PSMA) suggests that this novel tracer can detect PC relapses and metastases with high contrast. The aim of this study was to investigate its biodistribution in normal tissues and tumour lesions.
Methods A total of 37 patients with PC and rising prostate-specific antigen (PSA) levels were subjected to ^{68}Ga-PSMA positron emission tomography (PET)/CT. Quantitative assessment of tracer uptake was performed 1 and 3 h post-injection (p.i.) by analysis of mean and maximum standardized uptake values ($SUV_{mean/max}$) of several organs and 65

A. Afshar-Oromieh (✉) · A. Malcher · F. L. Giesel · C. Kratochwil · S. Haufe · U. Haberkorn · C. M. Zechmann
Department of Nuclear Medicine, University Hospital of Heidelberg, Im Neuenheimer Feld 400,
69120 Heidelberg, Germany
e-mail: a.afshar@gmx.de

A. Malcher
e-mail: anna.malcher@gmx.de

F. L. Giesel
e-mail: f.giesel@dkfz.de

C. Kratochwil
e-mail: clemens.kratochwil@t-online.de

S. Haufe
e-mail: sabine.haufe@med.uni-heidelberg.de

U. Haberkorn
e-mail: uwe.haberkorn@med.uni-heidelberg.de

C. M. Zechmann
e-mail: christian.zechmann@med.uni-heidelberg.de

M. Eder · M. Eisenhut
Department of Radiopharmaceutical Chemistry, German Cancer Research Center, Im Neuenheimer Feld 280,
Heidelberg, Germany

M. Eder
e-mail: m.eder@dkfz.de

M. Eisenhut
e-mail: m.eisenhut@dkfz.de

H. G. Linhart
National Center for Tumor Diseases (NCT)/DKFZ,
Im Neuenheimer Feld 581,
69120 Heidelberg, Germany
e-mail: heinz.linhart@med.uni-heidelberg.de

B. A. Hadaschik
Department of Urology, University Hospital of Heidelberg,
Im Neuenheimer Feld 110,
Heidelberg, Germany
e-mail: boris.hadaschik@med.uni-heidelberg.de

T. Holland-Letz
Department of Biostatistics, German Cancer Research Center,
Im Neuenheimer Feld 280,
Heidelberg, Germany
e-mail: t.holland-letz@dkfz.de

U. Haberkorn
Clinical Cooperation Unit Nuclear Medicine, German Cancer Research Centre, Heidelberg, Germany

tumour lesions. Subsequently, tumour to background ratios were calculated.
Results The PET/CT images showed intense tracer uptake in both kidneys and salivary glands. Moderate uptake was seen in lacrimal glands, liver, spleen and in small and large bowel. Quantitative assessment revealed excellent contrast between tumour lesions and most normal tissues. Of 37 patients, 31 (83.8 %) showed at least one lesion suspicious for cancer at a detection rate of 60 % at PSA <2.2 ng/ml and 100 % at PSA >2.2 ng/ml. Median tumour to background ratios were 18.8 (2.4–158.3) in early images and 28.3 (2.9–224.0) in late images.
Conclusion The biodistribution of the novel ^{68}Ga-PSMA tracer and its ability to detect PC lesions was analysed in 37 patients. Within healthy organs, kidneys and salivary glands demonstrated the highest radiotracer uptake. Lesions suspicious for PC presented with excellent contrast as early as 1 h p.i. with high detection rates even at low PSA levels.

Keywords Prostate cancer · PET/CT · Positron emission tomography · PSMA · Prostate-specific membrane antigen

Introduction

Prostate-specific membrane antigen (PSMA) is a cell surface protein with a significantly increased expression in prostate cancer cells when compared to other PSMA-expressing tissues such as kidney, proximal small intestine or salivary glands [1, 2, 10]. Additional advantages of PSMA are its transmembrane location with a large extracellular domain. Its enzyme activity allows for development of specific inhibitors and their internalization after ligand binding [3]. This protein therefore provides a promising target for prostate carcinoma-specific imaging and therapy. One imaging method using PSMA as an antigen target is the antibody capromab pendetide (ProstaScint®) which is used for scintigraphy [4]. This molecule is usually labelled with ^{111}In and binds to the cytoplasmic (not to the extracellular) domain of PSMA, which is masked by the cell's plasma membrane. Therefore capromab cannot bind to viable cells [5]. Due to the long half-life of ^{111}In radiation exposure is usually much higher than positron emission tomography (PET) imaging, e.g. with a ^{68}Ga-labelled tracer. Antibodies like capromab pendetide present with a long circulation time leading to high background signals and subsequent reduced detection rates. In addition, scintigraphy techniques always show lower spatial resolution when compared to PET. Furthermore, imaging with radiolabelled antibodies is relatively complex: after injection, multiple acquisitions over several days are needed to obtain the best images with highest contrast between background and tumour lesions. Recently, second-generation antibodies targeting the extracellular domain of PSMA have been developed, but most of the above-mentioned problems remain [4]. Consequently there is a need for developing high-resolution PET imaging methods using the extracellular domain of PSMA.

More recently, methods have been developed to label PSMA ligands with ^{68}Ga, ^{99m}Tc and $^{123/124/131}$I enabling their use for PET imaging, more scintigraphy options and radioligand therapy [6–8]. Our initial experience with PET/CT using Glu-NH-CO-NH-Lys-(Ahx)-[^{68}Ga(HBED-CC)] (^{68}Ga-PSMA) suggests that this novel tracer can detect prostate carcinoma relapses and metastases with high contrast by targeting the extracellular domain of PSMA [9]. The aim of this study was to investigate the uptake of this PSMA ligand in normal tissue and to evaluate its applicability for tumour imaging by calculating the ratio between radiotracer uptake in tumour lesions and background.

Materials and methods

A total of 37 male patients (Table 1) underwent ^{68}Ga-PSMA PET/CT with native computed tomography (PET/CT) either to detect tumour lesions in cases of biochemical relapse to further clarify suspicious findings in other imaging modalities or to evaluate possible treatment with ^{131}I-labelled PSMA ligands in progressive disease following prior conventional treatment of prostate carcinoma (hormone therapy, chemotherapy, radiation therapy and/or surgery). The median age was 70.0 years (range 52–87) with a median Gleason score (GSC) of 7.0 (range 5–9) and a median prostate-specific antigen (PSA) level of 3.3 ng/ml (range 0.01–148 ng/ml).

According to the QUADAS tool for clinical studies, the spectrum of participants in our study is representative of patients likely to receive such PET/CT analyses in practice.

Imaging

Images were obtained with the ^{68}Ga-labelled HBED-CC conjugate of the PSMA-specific pharmacophore Glu-NH-CO-NH-Lys that was synthesized as described previously [7]. $^{68}Ga^{3+}$ (half-life 68.3 min) was obtained from a ^{68}Ge/^{68}Ga radionuclide generator [10] and complexed with the HBED-CC conjugate as previously published [7, 11]. The final product was dissolved in isotonic phosphate-buffered saline (PBS) with subsequent sterile filtration.

The ^{68}Ga-PSMA complex solution was applied to patients via an intravenous bolus (median 121.0 MBq, range 52–212 MBq). Variation of injected radiotracer activity was caused by the short half-life of ^{68}Ga and variable elution efficiencies obtained during the lifetime of the ^{68}Ge/^{68}Ga radionuclide generator. However, all activities injected were sufficient to detect tumour-specific tracer uptake. Care was taken that all preparations contained 2 nmol PSMA ligand and dosage was measured after ^{68}Ga labelling.

Table 1 Characteristics of all 37 patients investigated in this study

Patient no.	Age (years)	Dosage (MBq)	GSC	PSA (ng/ml)	Lymph node metastases	Bone metastases	Local relapse	Soft tissue metastases
1	70	120	7	1.13	0	0	1	0
2	**65**	**120**	**8**	**0.10**	**0**	**0**	**0**	**0**
3	72	96	7	2.00	1	0	0	0
4	68	105	9	36.00	2	>5	0	0
5	69	90	7	1.10	1	0	0	0
6	72	116	5	4.00	0	0	1	0
7	73	139	6	7.40	0	0	1	0
8	**66**	**123**	**7**	**0.80**	**0**	**0**	**0**	**0**
9	52	148	6	0.10	0	0	0	1
10	68	68	9	9.60	0	0	2	0
11	63	152	7	0.10	2	3	0	0
12	75	169	7	19.80	0	1	0	0
13	80	182	9	7.50	1	0	0	0
14	86	93	7	2.60	0	0	2	0
15	71	172	7	2.90	0	1	0	0
16	74	133	7	34.00	>5	0	0	0
17	56	103	9	148.00	0	>5	0	0
18	70	117	7	7.40	2	0	0	0
19	73	96	9	4.80	1	0	0	0
20	75	82	8	0.04	1	0	0	1
21	67	96	9	0.01	0	1	0	2
22	76	52	5	11.90	>5	0	0	0
23	71	130	7	31.00	>5	1	1	0
24	61	59	8	1.50	0	0	0	1
25	66	185	9	7.10	0	>5	1	0
26	**71**	**200**	**7**	**0.50**	**0**	**0**	**0**	**0**
27	87	121	8	2.90	0	0	1	0
28	73	130	8	3.30	0	0	0	1
29	65	212	6	11.20	0	0	2	0
30	62	65	7	1.70	0	1	0	0
31	**68**	**148**	**7**	**0.10**	**0**	**0**	**0**	**0**
32	73	79	8	10.60	1	0	0	0
33	**62**	**85**	**9**	**2.20**	**0**	**0**	**0**	**0**
34	82	148	7	14.60	1	0	0	0
35	62	142	9	3.80	>5	>5	0	0
36	**63**	**161**	**7**	**0.10**	**0**	**0**	**0**	**0**
37	60	154	9	4.20	0	>5	0	0

Boldface indicates patients without pathological tracer uptake in the PET/CT (n=6). Patients 10, 16, 34, 37, 38 and 42 were further investigated by biopsy or surgery (in all investigated suspicious lesions, prostate cancer was histologically confirmed)

A native whole-body CT scan was performed with 5-mm slices 1 and 3 h post-intravenous injection (p.i.). An increment of 0.8 mm was used to reconstruct images with a B31 kernel. Immediately after CT scanning, a whole-body PET image was acquired (matrix 256). For each bed position we used 3 min acquisition time with a 15.5-cm field of view (FOV). The emission data were corrected for randoms, scatter and decay. Reconstruction was conducted with an ordered subset expectation maximization algorithm (OSEM) with 4 iterations/8 subsets and Gauss-filtered to an in-plane spatial resolution of 3 mm at full-width at half-maximum (FWHM). Attenuation correction was performed using the non-enhanced computed tomography data. PET and CT were performed using the same protocol for every patient on a Biograph 6 PET/CT scanner (Siemens, Erlangen, Germany).

One patient (no. 7) was first investigated by 60 min of dynamic imaging prior to the above-mentioned imaging modalities.

Image evaluation

The mean and maximum standardized uptake values (SUV_{mean}/SUV_{max}) of brain, lacrimal glands, parotid glands, submandibular glands, lungs, mediastinal blood pool, liver, spleen, pancreas head, bowel and kidneys were analysed 1 and 3 h p.i. With regard to the intestine, SUV was measured at the localization with the highest radiotracer uptake.

For calculation of the SUV, circular regions of interest were drawn around areas with focally increased uptake in transaxial slices and automatically adapted to a three-dimensional volume of interest (VOI) with e.soft software (Siemens) at a 70 % isocontour.

SUV in late images were defined as increasing, decreasing or stable with intensity changes of >10 %, < −10 % or between −10 % and +10 % respectively.

Furthermore, lesions that were visually considered as suggestive of relapses or metastases of prostate cancer were counted and analysed with respect to their SUV_{mean} and SUV_{max}.

Statistical distribution of SUV_{mean} and SUV_{max} values was assessed visually and found to be approximately normal, with only a slight skewness to the right. Thus, SUV values of the above-mentioned organs and of the tumour lesions 1 and 3 h p.i. were compared using a paired sample *t* test and further evaluated by computing ratios between uptake and background. As background tissue we selected gluteal musculature.

Although formally not part of this study, 30 of the lesions with pathological radiotracer uptake in 6 patients were further investigated by biopsy or surgery (Table 1, patients 10, 16, 34, 37, 38 and 42). In all cases, prostate cancer was confirmed: 2 local relapses, 2 soft tissue metastases and 26 lymph node metastases.

To determine whether SUV_{mean} or SUV_{max} is the more stable parameter, we calculated their coefficient of variation (standard deviation divided by the respective average).

Statistical analysis

Significance of differences was evaluated by using paired *t* tests. A *p* value of <0.05 was considered statistically significant.

Results

None of the patients developed adverse events or clinically detectable pharmacological effects. Figure 1 demonstrates the maximum intensity projection (MIP) of a patient with normal biodistribution of Glu-NH-CO-NH-Lys-(Ahx)-[^{68}Ga(HBED-CC)] 1 h p.i. High-contrast images were obtained even with the lowest dose applied (Fig. 2). Average SUV_{mean} and SUV_{max} values of different tissues in all 37 patients analysed (1 and 3 h p.i.) are summarized in Fig. 3a and b, respectively.

Fig. 1 MIP of a patient with normal biodistribution of ^{68}Ga-PSMA 1 h after injection. Accumulation is seen in lacrimal and salivary glands, nasal mucosa, liver, spleen, bowel, kidneys and bladder

Intraindividual changes in SUV values (using both SUV_{mean} and SUV_{max}) between 1 and 3 h p.i. (increase, decrease and stable) were investigated in all 37 patients. The most reproducible trend was registered in spleen with almost all patients showing a decrease in radiotracer uptake. SUV values are summarized in the two following paragraphs for SUV_{mean} and SUV_{max} separately (Fig. 3a, b):

A statistically significant increase of SUV_{mean} 3 h p.i. was noted in the following organs: brain (+8 %), lacrimal glands (+10 %), parotid glands (+11 %) and submandibular glands (+6 %). A statistically significant decrease of SUV_{mean} between 1 and 3 h p.i. was observed in: background (−25 %), lungs (−30 %), blood pool (−21 %), liver (−9 %), spleen (−31 %), pancreas (−16 %) and kidneys (−10 %). SUV_{mean} also increased in the intestine (+12 %), however without statistical significance.

A statistically significant increase of SUV_{max} was detected in brain (+37 %), nasal mucosa (+16 %), lacrimal glands (+18 %), parotid glands (+16 %), submandibular glands (+13 %) and bowel (+13 %). An increase was also observed in liver (+7 %) and background (+1 %) without reaching statistical significance. Conversely, a statistically significant decrease of SUV_{max} between 1 and 3 h p.i. was observed in lungs (−12 %) and spleen (−26 %) and in blood pool (−2 %), pancreas (−8 %) and kidneys (−2 %) without statistical significance, respectively.

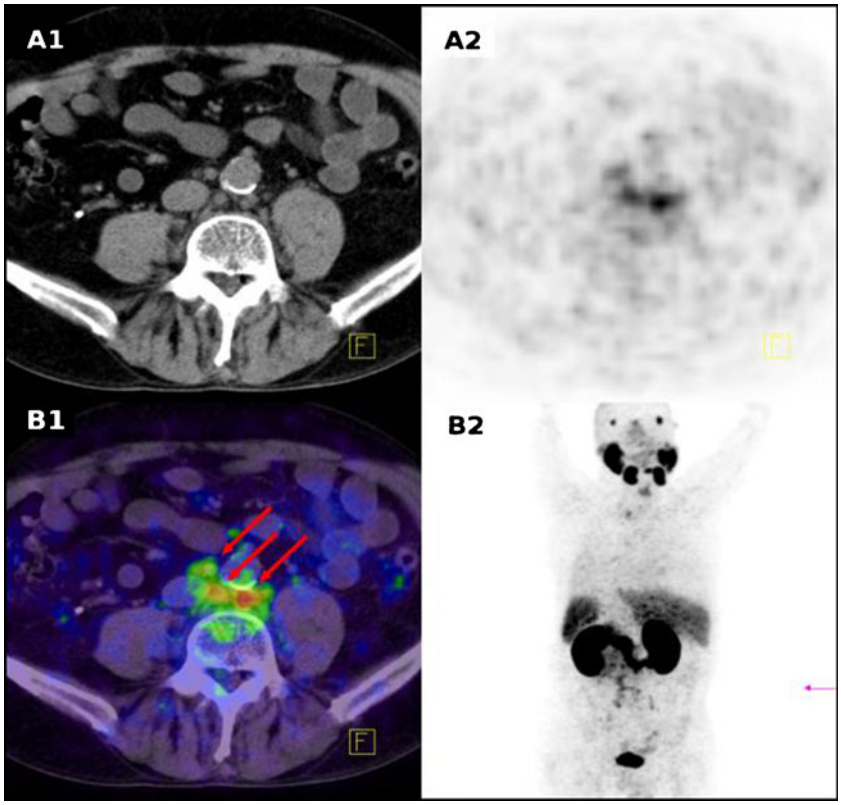

Fig. 2 ^{68}Ga-PSMA PET/CT of patient 22 who received the lowest dose of radiotracer (52 MBq). *Red arrows* point to several small lymph nodes with clearly visible pathological tracer uptake. *A1* CT, *A2* PET, *B1* fusion of PET and CT, *B2* MIP

All patients presented with a high radiotracer uptake in the proximal small intestine and to a lesser degree in other sections of the intestine. In 4 cases the highest intestinal uptake was detected in the descending colon, in all other 33 cases in the proximal small intestine.

To evaluate whether SUV_{mean} or SUV_{max} is the more stable parameter we calculated the coefficient of variation of both variables (standard deviations divided by the respective average values). In most tissues/organs the coefficient of variation was lower for SUV_{mean}, reflecting more stable values when evaluating images (raw data not shown, average values and standard deviation are shown in Fig. 2a,b).

Thirty-three patients had previously undergone prostatectomy, whereas four had been treated with prior radiation therapy and androgen deprivation without surgical removal of the prostate. All of these four patients presented with a slight radiotracer uptake in their prostate gland. Average SUV_{mean} values of the prostate and of local relapses of prostate cancer (n=11) 1 and 3 h after injection including standard deviation, median, minimum and maximum values are listed in Table 2.

In 31 patients at least one lesion suspicious for cancer was detected (e.g. Fig. 4) leading to a detection rate of 83.8 %. Patient characteristics are shown in Table 1.

Amongst all lesions visually considered typical for metastases or local relapses of prostate cancer we selected 65 representative lesions for further analysis (Fig. 5); 11 of them were defined as local relapses (Fig. 5, no. 1/11–12/14–15/22–23/44/54/57–58), 25 as bone metastases (Fig. 5, no. 5–9/18–20/24/30–34/41/43/50–53/59/61–62/64–65), 21 as lymph node metastases (Fig. 5, no. 2–4/10/16–17/21/25–29/35/37/39/45–48/60/63) and 8 were defined as soft tissue metastases in the pelvis without a clear correlation in the computed tomography (Fig. 5, no. 13/36/38/40/42/49/55–56).

SUV_{mean} (SUV_{max}) increased in 29 (44) lesions, decreased in 8 (6) lesions and remained stable in 28 (15) lesions between 1 and 3 h p.i. All of the lesions were clearly detectable both in early and late images. The median tumour to background ratio 1 (and 3) h p.i. was 18.8 (28.3), ranging from 2.4 (2.9) to 158.3 (224.0).

Patients with pathological radiotracer uptake (n=31) had a median PSA of 4.2 ng/ml (range 0.01–148), a median GSC of 7.0 (range 5–9) and were injected with a median of 120.0 MBq radiotracer (range 52–212).

Patients without pathological findings (n=6) had a median PSA of 0.3 ng/ml (range 0.1–2.2), a median GSC of 7 (range 7–9) and were injected with a median of 135.5 MBq radiotracer (range 82–200 MBq).

There was no significant difference in GSC and injected dosage between both groups. At PSA levels below 2.2 ng/ml, lesions suspicious for cancer were observed in 60 % of the patients. At PSA levels greater than 2.2 ng/ml, lesions were detected in all patients.

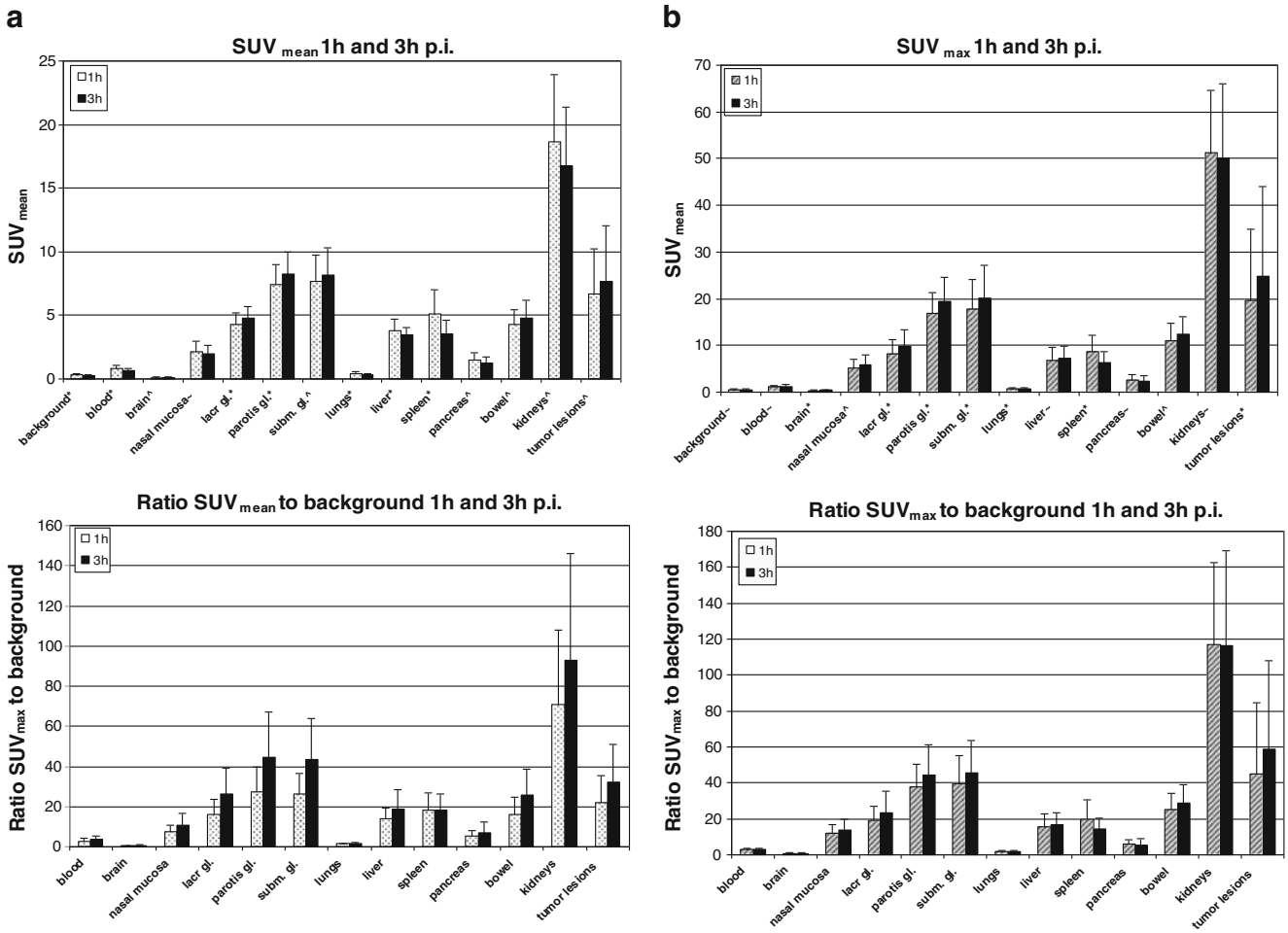

Fig. 3 Average $SUV_{mean/max}$ values (*top*) and average $SUV_{mean/max}$ to background ratios (*bottom*) in different tissues 1+3 h p.i. (tissues/organs: n=37, tumour lesions: n=65). Significance of differences between 1 and 3 h (t test): *p<0.001; ^p<0.05 and ~p>0.05

Patient 7 who was first investigated by 60 min of dynamic imaging presented with an earlier radiotracer uptake in a local PC relapse than radiotracer accumulation occurred in the urinary bladder (Fig. 8).

Discussion

PMSA is a cell surface protein which is expressed at high levels in prostate carcinoma cells when compared to other

Table 2 SUV_{mean} and SUV_{max} values of normal prostate tissue (n=4) and SUV_{max} values of local relapses of prostate cancer (n=11)

SUV_{mean}	Average SUV_{mean} 1 h p.i. (and 3 h p.i.)	Standard deviation 1 h p.i. (and 3 h p.i.)	Median 1 h p.i. (and 3 h p.i.)	Minimum 1 h p.i. (and 3 h p.i.)	Maximum 1 h p.i. (and 3 h p.i.)
Prostate gland	2.9 (2.4)	±0.1 (±0.2)	2.9 (2.4)	2.7 (2.1)	3.1 (2.7)
SUV_{max}	Average SUV_{max} 1 h p.i. (and 3 h p.i.)	Standard deviation 1 h p.i. (and 3 h p.i.)	Median 1 h p.i. (and 3 h p.i.)	Minimum 1 h p.i. (and 3 h p.i.)	Maximum 1 h p.i. (and 3 h p.i.)
Prostate gland	3.5 (4.0)	±0.5 (±1.6)	3.5 (3.8)	3.0 (2.3)	4.1 (5.9)
SUV_{max}	Average SUV_{max} 1 h p.i. (and 3 h p.i.)	Standard deviation 1 h p.i. (and 3 h p.i.)	Median 1 h p.i. (and 3 h p.i.)	Minimum 1 h p.i. (and 3 h p.i.)	Maximum 1 h p.i. (and 3 h p.i.)
Local relapses of prostate cancer	4.2 (13.0)	±7.3 (±13.1)	4.6 (5.1)	2.2 (3.0)	26.8 (38.8)

This table demonstrates low uptake of normal prostate tissue as well as elevated uptake in cases of local relapse of prostate cancer

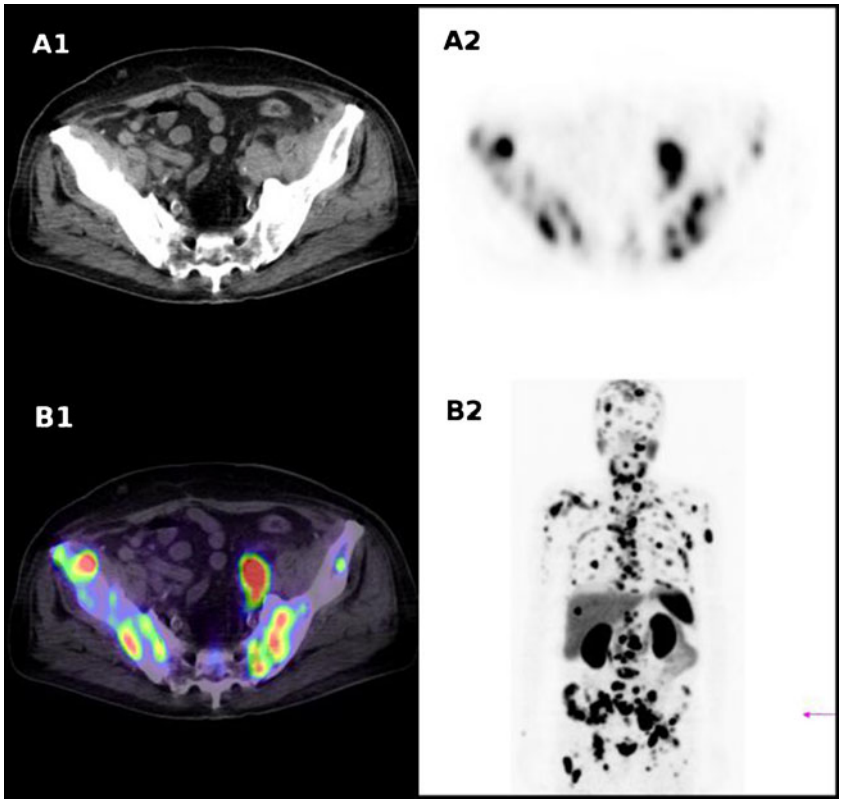

Fig. 4 ^{68}Ga-PSMA PET/CT demonstrating a patient representative for disseminated lymph node and bone metastases of prostate cancer. *A1* CT, *A2* PET, *B1* fusion of PET and CT, *B2* MIP

PSMA-expressing tissues [3, 12, 13]. Therefore, this protein may serve as a target for imaging and therapy of prostate cancer. In order to assess the applicability of tumour imaging with a radiolabelled PSMA ligand we evaluated the biodistribution of the ^{68}Ga-PSMA complex Glu-NH-CO-NH-Lys-(Ahx)-[^{68}Ga(HBED-CC)] in normal tissues and determined the ratio of radiotracer uptake between tumour lesions and background.

PSMA expression, mostly at low levels, has been reported for various tissues [12, 13]. In agreement with these data our imaging analysis demonstrated significant radiotracer uptake in salivary glands and kidneys only and to a lesser extent in lacrimal glands, liver, spleen and bowel as well as normal prostate tissue itself. In addition, salivary and lacrimal glands showed a slight increment of radiotracer uptake between 1 and 3 h p.i. This is suggestive of radiotracer trapping and might contribute to side effects during treatment with radiolabelled PSMA ligands. However, in most other organs our data demonstrate relatively stable uptake values between 1 and 3 h p.i.

Amongst normal tissues, SUV_{mean} decreased between 1 and 3 h p.i. in background, lungs, mediastinal blood pool,

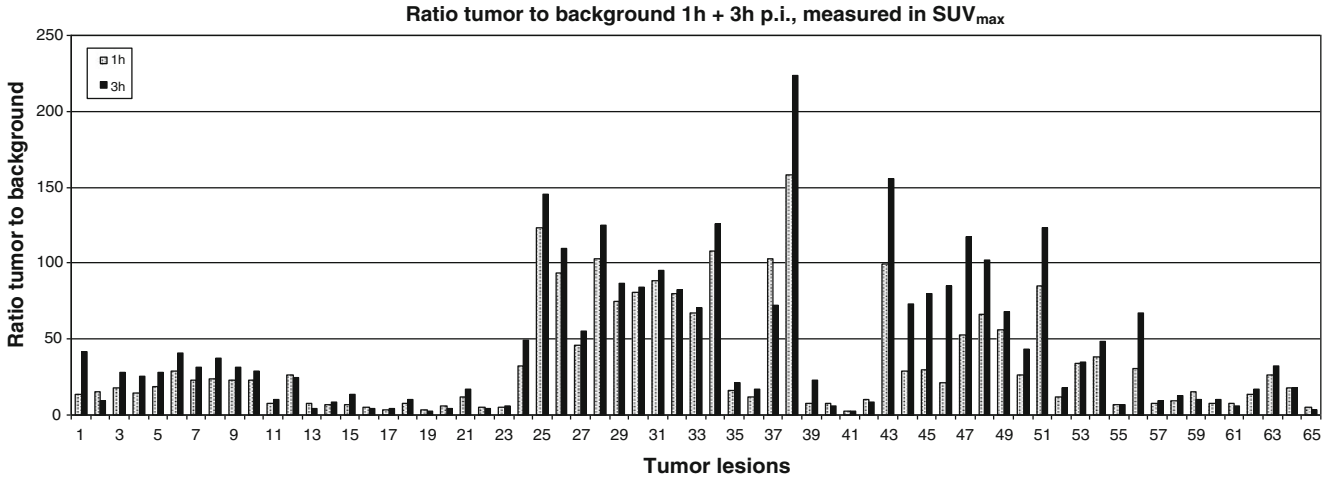

Fig. 5 Ratios between uptake (measured in SUV_{max}) and background of 65 representative tumour lesions 1+3 h p.i., range 2.4 (no. 41) to 224 (no. 38)

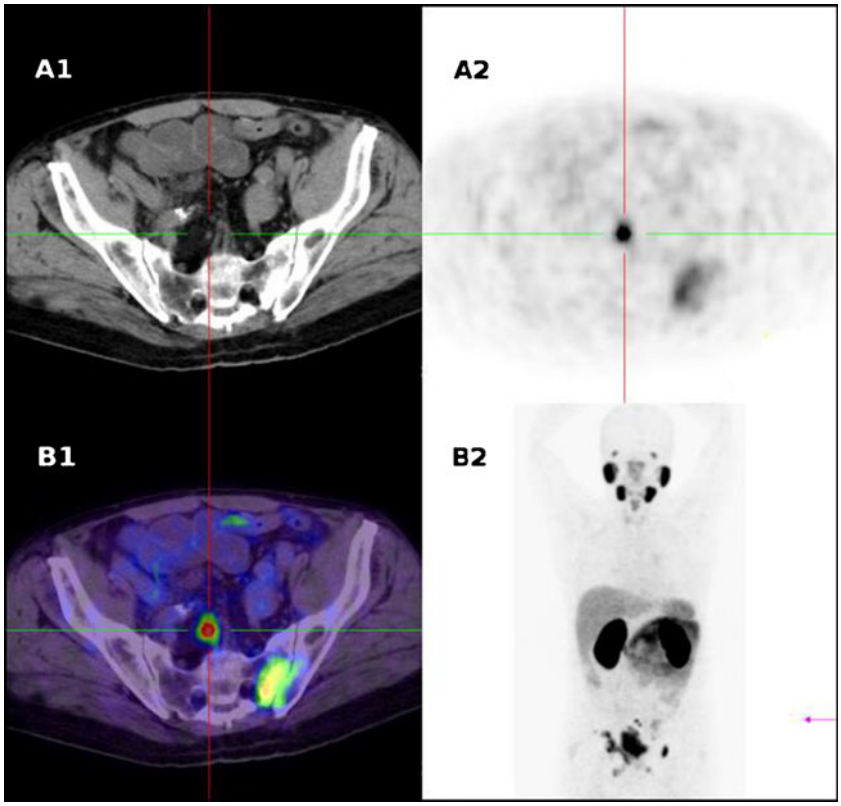

Fig. 6 ^{68}Ga-PSMA PET/CT of patient 4 with multiple lymph node and bone metastases of prostate cancer. Even small lymph node metastases (as pinpointed by the intersecting lines) frequently exhibit an excellent contrast.*A1* CT, *A2* PET, *B1* fusion of PET and CT, *B2* MIP

liver and spleen. In these organs PSMA expression is reported to be low [12, 13]. Thus, we hypothesize that radioactivity measured in these tissues mostly reflects a blood pool effect. The most likely reason for the decrease

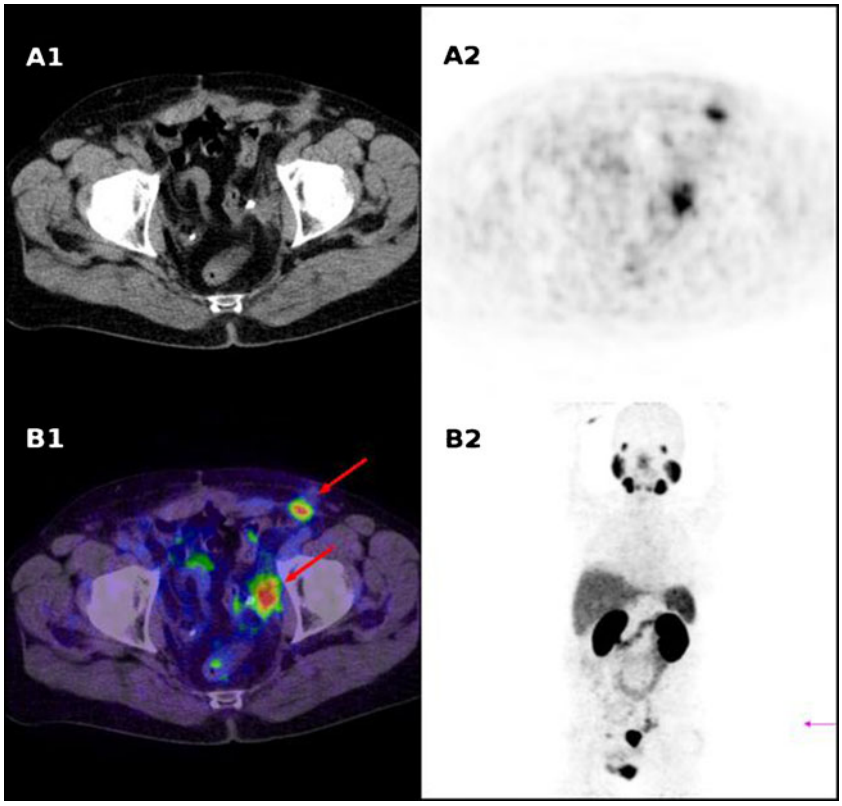

Fig. 7 ^{68}Ga-PSMA PET/CT of patient 21 with a minimal PSA value (0.01 ng/ml). *Red arrows* point to typical lymph node metastases. The combination of minimal PSA levels despite visible tumour lesions suggests a dedifferentiation of the prostate cancer. *A1* CT, *A2* PET, *B1* fusion of PET and CT, *B2* MIP

of measured SUV values in the above-mentioned tissues is the plasma clearance of the radiotracer. However, we cannot exclude that the ^{68}Ga-labelled PSMA ligand as a small molecule [7] redistributes from the intravascular compartment to the interstitial space with time. This would have to be investigated by further analysis.

The SUV_{mean} also decreased significantly in the pancreatic head and kidneys. While the mechanism remains unclear in the pancreas, excretion of radioactive urine into the bladder is the most likely reason for the SUV reduction of the kidneys in late images.

Only four patients had no previous prostatectomy and all of them showed a moderate radiotracer uptake in the prostate. Nevertheless, we cannot exclude that prior therapies (such as radiation and antihormonal therapy) might have affected the tracer uptake.

In the literature PSMA expression in the intestine has mostly been described for the proximal small intestine [13—15]. Nevertheless, all of our patients also showed radiotracer uptake in other parts of the intestine. However, in agreement with the expression data, the highest uptake was measured in the proximal small intestine in 33 patients, whereas in 4 cases this was observed in the descending colon. We suggest that uptake in the colon reflects PSMA expression in neuroendocrine cell populations of colonic crypts or physiological regeneration areas [12, 13]. In our study there was no evidence of radiotracer clearance via the biliary tract. Visualization of the gall bladder was not observed in our patient population.

Radiotracer detection in nasal mucosa could be explained either by PSMA expression in areas of tissue regeneration or by a blood pool effect.

Our study further demonstrates that metastases and recurrent prostate cancer usually present with excellent contrast already 1 h p.i. of the ^{68}Ga-PSMA ligand contributing to an excellent detection rate of lesions suspicious for cancer even at low PSA levels. We hypothesize that the detection rate will increase with rising PSA level and tumour size, even though small lymph node metastases also frequently presented with excellent contrast (Fig. 6). In addition, our data show the capability of this PSMA ligand to detect lesions of obviously dedifferentiated (minimal PSA levels despite multiple metastases and low initial GSC) prostate carcinoma (Fig. 7).

PSMA-negative prostate carcinoma seems to be rare [2, 16]. However, we cannot exclude the possibility of false-negative PET/CT imaging data in patients with elevated PSA levels (e.g. patient 33).

Further analyses are required to confirm our findings and to further evaluate the characteristics of different types of metastases. In addition, the question should be addressed if lymph node metastases close to organs with high tracer accumulation could be detected with improved contrast in late images.

Imaging of prostate cancer and its local metastases could be concealed by the overwhelmingly abundant radioactivity in the urinary bladder. Thus, it is recommended that the bladder be emptied prior to imaging. Further analyses are required to address the question if dynamic imaging with early images might improve detection of lesions close to the urinary bladder (Fig. 8).

SUV_{mean} values demonstrated less variability than SUV_{max} values. Nevertheless, we propose the use of SUV_{max} due to its higher reproducibility between investigators: Each investigator will receive the same SUV_{max} values in a VOI, whereas SUV_{mean} values strongly depend on the size selection of the VOI.

We suggest that late imaging (e.g. 3 h p.i.) should be used only in cases of unclear lesions. This is supported by the observation that all of the 65 lesions suspicious for cancer were clearly seen both in early and late images. Nevertheless, this has to be confirmed by further analysis of larger cohorts. Also the most interesting question of whether PSMA ligands could replace PET imaging with choline-based tracers has to be addressed by further studies.

Conclusion

This study presents the biodistribution of Glu-NH-CO-NH-Lys-(Ahx)-[^{68}Ga(HBED-CC)] in 37 patients. Within healthy organs, kidneys and salivary glands demonstrated the highest radiotracer uptake, whereas lacrimal glands, liver, spleen and bowel showed relatively moderate uptake. Lesions suspicious for prostate carcinoma presented with excellent contrast as early as 1 h p.i. with high detection rates even at low PSA levels. Late images (e.g. 3 h p.i.) may help to further clarify unclear lesions.

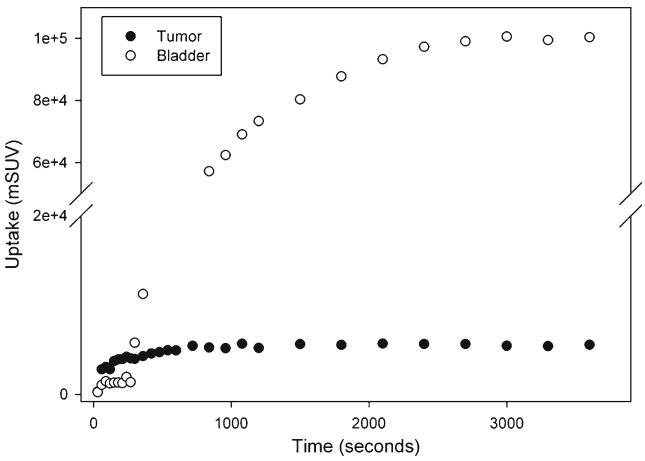

Fig. 8 Time-activity curves of the urinary bladder and a local relapse of patient 7 demonstrating an earlier radiotracer uptake in the relapse than radiotracer accumulation occurred in the urinary bladder

Acknowledgments We thank our staff for their help in performing this study.

Conflicts of interest None.

References

1. Sweat SD, Pacelli A, Murphy GP, Bostwick DG. Prostate-specific membrane antigen expression is greatest in prostate adenocarcinoma and lymph node metastases. Urology 1998;52(4):637–40.
2. Mannweiler S, Amersdorfer P, Trajanoski S, Terrett JA, King D, Mehes G. Heterogeneity of prostate-specific membrane antigen (PSMA) expression in prostate carcinoma with distant metastasis. Pathol Oncol Res 2009;15(2):167–72.
3. Ghosh A, Heston WD. Tumor target prostate specific membrane antigen (PSMA) and its regulation in prostate cancer. J Cell Biochem 2004;91:528–39.
4. Bander NH. Technology insight: monoclonal antibody imaging of prostate cancer. Nat Clin Pract Urol 2006;3(4):216–25.
5. Liu H, Moy P, Kim S, Xia Y, Rajasekaran A, Navarro V., et al. Monoclonal antibodies to the extracellular domain of prostate-specific membrane antigen also react with tumor vascular endothelium. Cancer Res 1997;57(17):3629–34.
6. Hillier SM, Maresca KP, Femia FJ, Marquis JC, Foss CA, Nguyen N., et al. Preclinical evaluation of novel glutamate-urea-lysine analogues that target prostate-specific membrane antigen as molecular imaging pharmaceuticals for prostate cancer. Cancer Res 2009;69(17):6932–40.
7. Eder M, Schäfer M, Bauder-Wüst U, Hull WE, Wangler C, Mier W., et al. (68)Ga-complex lipophilicity and the targeting property of a urea-based PSMA inhibitor for PET imaging. Bioconjug Chem 2012;23:688–97.
8. Banerjee SR, Foss CA, Castanares M, Mease RC, Byun Y, Fox JJ., et al. Synthesis and evaluation of technetium-99m- and rhenium-labeled inhibitors of the prostate-specific membrane antigen (PSMA). J Med Chem 2008;51(15):4504–17.
9. Afshar-Oromieh A, Haberkorn U, Eder M, Eisenhut M, Zechmann C. [(68)Ga]Gallium-labelled PSMA ligand as superior PET tracer for the diagnosis of prostate cancer: comparison with (18)F-FECH. Eur J Nucl Med Mol Imaging 2012;39(6):1085–6.
10. Schuhmacher J, Maier-Borst W. A new 68Ge/68Ga radioisotope generator system for production of 68Ga in dilute HCl. Int J Appl Radiat Isot 1981;32:31–6.
11. Schäfer M, Bauder-Wüst U, Leotta K, Zoller F, Mier W, Haberkorn U., et al. A dimerized urea-based inhibitor of the prostate-specific membrane antigen for 68Ga-PET imaging of prostate cancer. EJNMMI Res 2012;2(1):23.
12. Human protein atlas. FOLH1. http://www.proteinatlas.org/ENSG00000086205/normal.
13. Silver DA, Pellicer I, Fair WR, Heston WD, Cordon-Cardo C. Prostate-specific membrane antigen expression in normal and malignant human tissues. Clin Cancer Res 1997;3(1):81–5.
14. Gordon IO, Tretiakova MS, Noffsinger AE, Hart J, Reuter VE, Al-Ahmadie HA. Prostate-specific membrane antigen expression in regeneration and repair. Mod Pathol 2008;21(12):1421–7.
15. Maraj BH, Aldersley MA, Markham AF. Prostate-specific membrane antigen expression in the duodenum: implications in coeliac disease and immunotherapy for prostate cancer. Lancet 1998;351(9115):1559–60.
16. Bostwick DG, Pacelli A, Blute M, Roche P, Murphy GP. Prostate specific membrane antigen expression in prostatic intraepithelial neoplasia and adenocarcinoma: a study of 184 cases. Cancer 1998;82(11):2256–61.